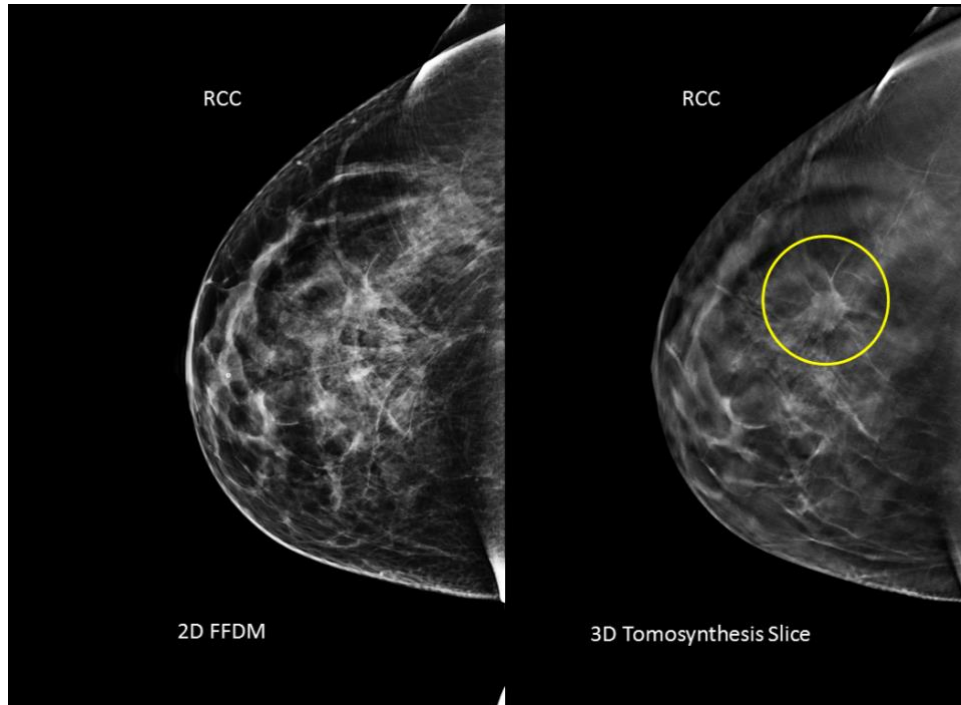


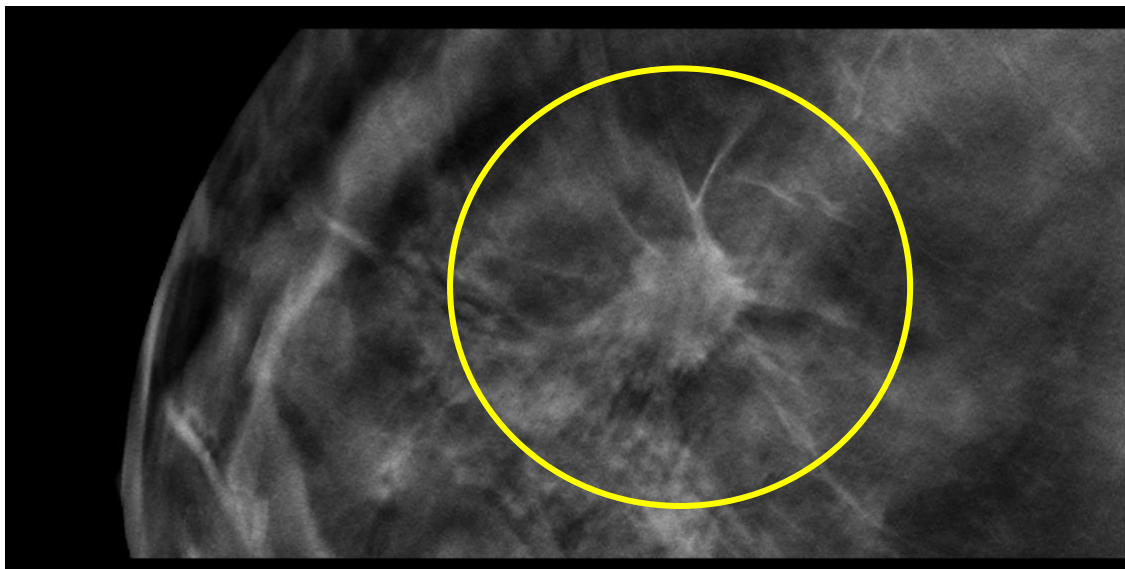
## WS12-015

### Description:

- 46 yo patient presents for routine screening mammogram
- 2D conventional mammogram essentially negative
- 3D Tomosynthesis reveals a 15 mm spiculated mass between slices 38-48, best demonstrated on slice 43.
- Pathology Invasive Ductal Carcinoma, grade 2



Full Breast Images with annotation



Region of Interest (ROI) with annotation